

**Title: Study of histopathological effects of electromagnetic field (EMF) on the thyroid gland
of rats**

**Masoumeh Akhgar Maryan^a, Ahmad Reza Raji^{b*}, Mohsen Maleki^c, Morteza kaffae
Razavi^d**

Correspondence: Dr. Ahmad Reza Raji

Postal address: Department of Basic sciences, Faculty of Veterinary medicine, Ferdowsi

University of Mashhad, Mashhad, Iran Email: rajireza@um.ac.ir Orcid ID: 0000000281928374

Tel: 09153050349

Keywords: Histopathology, Electromagnetic field, Thyroid gland, Rat

Abstract:

The relationship between exposures to Electromagnetic field (EMF) and human health is more in focus. Some studies showed the possible relation between exposure to EMF and cancer.

The thyroid gland is one of the most exposed and vital organ and may be a target for any type of electromagnetic radiation; therefore, we studied histopathological effects of electromagnetic field (EMF) on the thyroid gland of rat.

In this research, 35 healthy rats were used. The animals were divided to five groups, and then all animals were exposed to 2100MHz (4G) frequency for 0, 15, 60, 120, 180 min every day for a period of 70 days. The animals were euthanized by removing of blood from the heart then tissue samples were prepared from thyroid gland and stained with hematoxylin and eosin (H&E) and Mason trichrome (MT). Stereological studies were done by the Cavalier's principle.

Following the EMF exposure, a significant decrease ($p < 0.05$) in the diameter of the thyroid follicles, heights of epithelial follicles and thyroid follicles volume were recorded in 180 min exposure groups.

In the EMF exposure groups (120 and 180 min) histopathological effect observed include follicles with decreased colloid, congestion and increase of connective tissue. We also observed formation of apoptotic body that infiltrated inside of follicle and follicular cells with condensed nuclei under the exposure of EMF for 120 and 180 min.

We concluded that exposure of EMF (4G) for over 120 min for 70 consecutive days has histopathological and stereological effects in thyroid gland in rats.

Abbreviations:

EMF: Electromagnetic field

TCs: Thyrocyte

T3: Triiodothyronine

T4: Thyroxin

TSH: Thyroid-stimulating hormone

Introduction:

With the development of technologies, human exposure of electromagnetic field (EMF) has increased during the recent years. In 2021, mobile phone subscriptions surpassed eight billion users worldwide, and the number is expected to increase to 8.8 billion by 2026 [1]. Non-ionizing forms of radiation include lower frequencies on the electromagnetic spectrum and are not proven to cause DNA damage directly [2].

Several studies showed the possible relation between exposure to EMF and certain malignancies including lymphomas, leukemia, breast, brain and lung cancers [3-5]. International agency for Research on Cancer (IARC) has classified EMF as possibly carcinogenic to humans [6].

EMF causes morphological and functional changes in endocrine system, central nervous system, immune systems, cardiovascular system, reproductive system, learning and memory [7, 8]. The thyroid gland may be particularly vulnerable to this effect because of its normal anatomical position near the neck.

The finding of another study revealed that exposure of electromagnetic fields with a 940 MHz frequency has increased the permeability of blood brain barrier (BBB) [9]. Previous studies have reported that EMF exposure in rats caused a decreased uptake of iodine by the thyroid gland and reduced levels of plasma TSH [10]. Another research has reported that EMF (50MHz) exposure increased cyclic adenosine monophosphate (cAMP), T3 and T4 [11]. In another study, exposure of EMF (50MHz) for 2-6 month by using light and transmission electron microscopy revealed the frequent findings of several colloid droplets within the same thyrocyte with the occasional presence of large-diameter droplets and alterations in lysosomes, granular endoplasmic reticulum and cell nuclei compared to the control group [12]. Another research was designed that were epigenetic effect of 50 Hz EMF in vitro, showed alteration of genome-wide methylation and DNMTs expression may play an important role in the biological effect in mouse spermatocyte. [13].

Questions have been raised about the safety of prolonged use of EMF in mobile phone and other equipment. Therefore, in the present study, we aimed to investigate the possible harmful effect of EMF (2100MHz) (4G) on thyroid gland. This paper will focus on new generation of EMF (4G) exposure on thyroid gland by using EMF generator.

Results:

Stereological findings:

Following the EMF exposure were showed in diameter of the thyroid follicles significant increase in 15 min and decrease in 180 min ($p < 0.005$) (Graph: 1), for heights of thyrocyte were decreased with increased the time of exposure but have not significant change (Graph: 2) and for thyroid follicles volume significant decreased in 180 min exposure of EMF (Graph: 3).

Histopathological finding:

The results of the studies showed that in the control group (0 min) (Fig: 1) and EFM exposure group (15 min.) tissue characteristics including follicles, thymocyte cells, colloidal materials, connective tissue and capsule of the thyroid gland were observed as normal.

Histopathological finding in the EMF exposure groups (60 and 120 min.) include: collapsed follicles with little colloid, congestion and increased apoptotic bodies. (Fig: 2). We also observed apoptotic bodies (AB) within follicles, rupture of follicles, and TCs with heterochromatin nuclei were infiltrated in interfollicular septa on the thyroid gland that exposure of EMF for 120 and 180 min. (Fig: 2, 3).

The results showed that the connective tissue between the thyroid follicles in all of the exposed groups had increased compared to the control group but the only difference between groups of 120 and 180 min were statistically significant ($P < 0.005$) (Fig: 4) (Graph: 3).

Discussion:

In 2021, mobile phone subscriptions surpassed eight billion users worldwide, and the number is expected to increase to 8.8 billion by 2026 [1].

The relationship between exposures to EMF and human health is very important. The present study confirms previous finding and contributes additional evidence about histological effects of EMF (4G) exposure on thyroid gland in rats.

The results of this study showed that the diameter of the thyroid follicles increased significantly in the exposure of EMF after 15 min, and with the increase in the time of the influence of the waves, it decreased up to 180 min, and this decrease was significant in 180 min. The reason for this initial increase is not known to us, but with the increase in the time of impact of the waves on the cells, maybe with cell organelles were damaged and with the decrease in the secretion of thyroid hormones, the diameter of the thyroid follicles decreases. We were observed that with increased of time of exposure of EMF the height of thyrocyte decreased but not significantly and we were observed that with increased of time of exposure of EMF the thyroid follicles volume significantly decreased in 180 minute and connective tissue volume significantly increased in 180 minute. We concluded that with increased of time of exposure EMF ,it causes the destruction of cell organelles and DNA of nuclear, and after that, with the decreased in the height of thyrocyte, the secretion of hormones were decreased, and then the volume of follicles were decreased and the volume of connective tissue were increased.

This study showed pathological effects of TCs after exposure of EMF including contracted follicles with decreased colloid, congestion and extension of connective tissue in interstitial space. Also we were observed formation of apoptotic bodies within follicles and follicular cells with condensed nuclei in thyroid gland of the rats under the exposure of EMF for 180 min that it was consistent with other research [14].

Some researcher revealed that mobile phone radiofrequency radiation might be associated with thyroid gland insufficiency and alterations in serum thyroid hormone levels, with a possible disruption in the hypothalamic-pituitary-thyroid axis [15].

Other researcher concluded that EMF exposure at the frequency of 1800 MHz has caused significant changes in the levels of serum TSH, T4, MDA, and MCT8 concentration in the Wistar rats [16].

Our work shows a dilation and an increase in the number of blood capillary in thyroid gland, which is similar to other researches [12]. Some scientists showed effect of that EMF exposure on mast cells population and degranulation of these cells; therefore, EMF increases released of some mediator from mast cell [17].

According to the obtained results, the long-term use of electromagnetic waves can inhibit the growth and differentiation of cells by affecting the vital mechanisms.

Materials and methods:

To do this research, for the first time an electromagnetic generator, an antenna (output power: 2000 MW, power source lithium-ion battery 127, 2600 MAH) was used with a variable frequency band (2100 to 2600 MHz) (Fig.4).

In this study, 35 healthy adult male Wistar rats aged 2 months old and weighing 300-350 gram were used. The rats purchased from the laboratory animal unit, Mashhad University of Medical sciences, Mashhad, Iran. The Wistar rats were kept in a 12h light: 12h dark cycle, at constant temperature of 25°C, while food and water were accessible on an ad libitum basis. Animals were randomly divided into five groups, each of which consisted of 7 animals. Groups exposed to 2100 MHz frequency continuously for 0, 15, 60, 120, 180 min every day for a period of 70 days. The animals were anesthiad with CO₂ and after dissection of abdominal cavity, they were euthanized

by removing of blood from the heart. Then thyroid glands were removed and the samples collected.

Then the samples were fixed in 10% neutral buffered formalin solution. Thyroid samples were transferred from formaldehyde, after dehydration by passing tissue through a series of alcohol solutions, were cleared in xylene and were embedded in paraffin (Merck, Germany). Then the specimen were embedded in large block of paraffin by paraffin dispenser (Didsabz, Iran). Then sample were sectioned at 5 μm thickness using microtome (Leica, Germany). The final step was staining sample with Hematoxylin and eosin (H &E) and Masson trichrome (MT) (Merck, Germany). All the procedures were certified by the relevant Ethical Committee of Ferdowsi University of Mashhad, Mashhad, Iran (Code: IR.UM.REC.1401.089).

Data were analyzed by one-way ANOVA, (statistical package of SPSS version 19). In all tests, $p \leq 0.05$ was considered as statistically significant.

Stereology:

Stereological studies were done by the Cavalier's principle in order to estimate the epithelial height, follicular thickness, follicular volume and connective tissue volume in septa [18]. For this purpose, 10 sections were selected from each specimens and photographed by a camera (Olympus/DP25) with light microscope (Olympus CX22). A point grid was used for point counting. Grid was cited on the figures, each parameter was counted, and thyroid gland was blindly estimated by the following formula:

$$V (\text{mm}^3) = d \times \Sigma p \times a (p)$$

d = Interval between section and section thickness; Σp = total number of point considered on the area of sections; $a (p)$ = the area represented of each point in the grid.

Acknowledgements

This study received financial support in the form of Research Project No. 41587 from research council of Ferdowsi University of Mashhad, Mashhad, Iran. We would like to thank all the colleagues for their corporations.

Competing Interests

The authors declare no conflict of interest.

References:

1. Jonsson P, Carson S, Davis S. et al. Ericsson mobility report. 2021 <https://www.ericsson.com/en/mobility-report/reports/june-2021>.
2. Potenza L, Cucchiaroni L, Piatti E, Angelini U, Dachà M. Effects of high static magnetic field exposure on different DNAs. *Bioelectromagnetics: Journal of the Bioelectromagnetics Society, the Society for Physical Regulation in Biology and Medicine, the European Bioelectromagnetics Association.* 2004; 25(5):352-5. doi:10.1002/bem.10206
3. Ahlbom A. Neurodegenerative diseases, suicide and depressive symptoms in relation to EMF. *Bioelectromagnetics: Journal of the Bioelectromagnetics Society, the Society for Physical Regulation in Biology and Medicine, the European Bioelectromagnetics Association.* 2001; 22(S5):S132-43 doi: 10.1002/1521-186x (2001)22:5+<: aid-bem1029>3.3.co; 2-m
4. Capko D. Transepithelial depolarization in breast cancer. *Breast Cancer Res. Treat.* 1996; 41:230.
5. Grundler W, Kaiser F, Keilmann F, Walleczek J. Mechanisms of electromagnetic interaction with cellular systems. *Naturwissenschaften.* 1992; 79:551-9. doi: 10.1007/BF01131411.
6. International Agency for Research on Cancer. Working Group on the Evaluation of Carcinogenic Risks to Humans. Non-ionizing radiation, Part 1: static and extremely low-frequency (ELF) electric and magnetic fields. *IARC Monogr Eval Carcinog Risks Hum.* 2002; 80:1-395.

7. Szemerszky R, Zelena D, Barna I, Bárdos G. Stress-related endocrinological and psychopathological effects of short-and long-term 50 Hz electromagnetic field exposure in rats. *Brain research bulletin*. 2010; 15; 81(1):92-9. doi: 10.1016/j.brainresbull.2009.10.015.
8. Zagorskaia EA. Endocrine responses to low frequency electromagnetic fields of continuous and intermittent generation. *Kosm Biol Aviakosm Med*. 1989; 23:4-14.
9. Razavi MK, Raji AR, Maleki M, Dehghani H, Haghpeima A. Histopathological and immunohistochemical study of rat brain tissue after exposure to mobile phone radiation. *Comparative Clinical Pathology*. 2015; 24:1271-6. doi: 10.1007/s00580-015-2113-0
10. Koyu A, Cesur G, Ozguner F, Akdogan M, Mollaoglu H, Ozen S. Effects of 900 MHz electromagnetic field on TSH and thyroid hormones in rats. *Toxicology letters*. 2005; 4; 157(3):257-62. doi: 10.1016/j.toxlet.2005.03.006
11. Ross CL, Teli T, Harrison BS. Effect of electromagnetic field on cyclic adenosine monophosphate (cAMP) in a human mu-opioid receptor cell model. *Electromagnetic Biology and Medicine*. 2016; 2; 35(3):206-13. doi: 10.3109/15368378.2015.1043556
12. Rajkovic V, Matavulj M, Johansson O. Light and electron microscopic study of the thyroid gland in rats exposed to power-frequency electromagnetic fields. *Journal of experimental biology*. 2006; 1; 209(17):3322-8. doi: 10.1242/jeb.02375
13. Liu Y, Liu WB, Liu KJ, Ao L, Zhong JL, Cao J, Liu JY. Effect of 50 Hz extremely low-frequency electromagnetic fields on the DNA methylation and DNA methyltransferases in mouse spermatocyte-derived cell line GC-2. *BioMed Research International*. 2015; 3; 2015. doi: 10.1155/2015/237183
14. Blumenthal, N.C., Ricci, J., Breger, L., Zychlinsky, A., Solomon, H., Chen, G.G., Kuznetsov, D. and Dorfman, R. Effects of low-intensity AC and/or DC electromagnetic fields on cell

attachment and induction of apoptosis. *Bioelectromagnetics: Journal of the Bioelectromagnetics Society, The Society for Physical Regulation in Biology and Medicine, The European Bioelectromagnetics Association*, 1997; 18(3), pp.264-272. doi: 10.1002/ (sici)1521-186x(1997)18:3<264::aid-bem10>3.0.co;2-p

15. Alkayyali T, Ochuba O, Srivastava K, Sandhu JK, Joseph C, Ruo SW, Jain A, Waqar A, Poudel S. An exploration of the effects of radiofrequency radiation emitted by mobile phones and extremely low frequency radiation on thyroid hormones and thyroid gland histopathology. *Cureus*. 2021; 20; 13(8). doi.org/10.1002/ (SICI) 1521-186X(1997)18:3<264::AID-BEM10>3.0.CO;2-P

16. Zufry H, Rudijanto A, Soeatmadji DW, Sakti SP, Munadi K, Sujuti H, Mintaroem K. Effects of mobile phone electromagnetic radiation on thyroid glands and hormones in *Rattus norvegicus* brain: An analysis of thyroid function, reactive oxygen species, and monocarboxylate transporter. *Journal of Advanced Pharmaceutical Technology & Research*. 2023; 1; 14(2):63-8. doi: 10.4103/japtr.japtr_680_22

17. Rajkovic V, Matavulj M, Johansson O. Histological characteristics of cutaneous and thyroid mast cell populations in male rats exposed to power-frequency electromagnetic fields. *International journal of radiation biology*. 2005; 1; 81(7):491-9. doi: 10.1080/09553000500303518

18. Altunkaynak BZ, Altunkaynak E, Unal D, Unal B. A novel application for the cavalieri principle: a stereological and methodological study. *The Eurasian journal of medicine*. 2009; 41(2):99.

Figure legends:

Figure1: Photomicrograph of thyroid gland from control group (0 min). It shows normal Follicle (F), Connective tissue (CT), Thyrocyte (T) and Colloid. H&E staining $\times 100$.

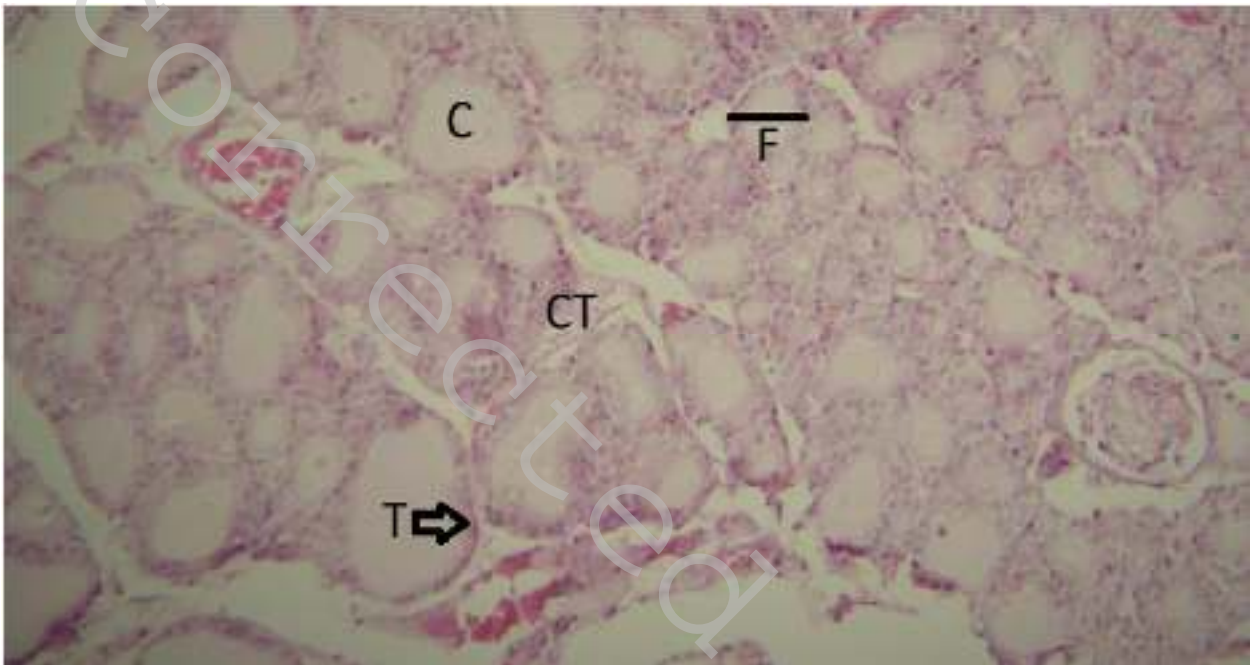


Figure 2: Photomicrograph of thyroid gland from animals exposed to 2100 MHz (group: 120 min).

It shows numerous small follicles (MF) with decreased colloid and low height of TCs (T), congestion (BC) and more apoptotic bodies (AB), H& E staining $\times 400$.

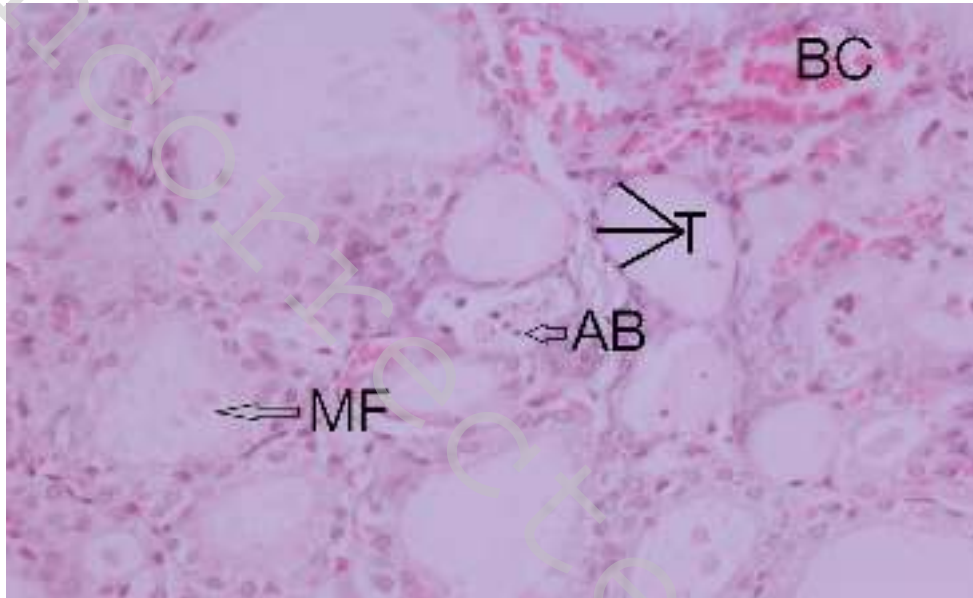


Figure 3: Photomicrograph of thyroid gland from animal exposed to 2100 MHz (group: 180 min).

It shows apoptotic bodies (AB), rupture of follicles (RF) $\times 400$.

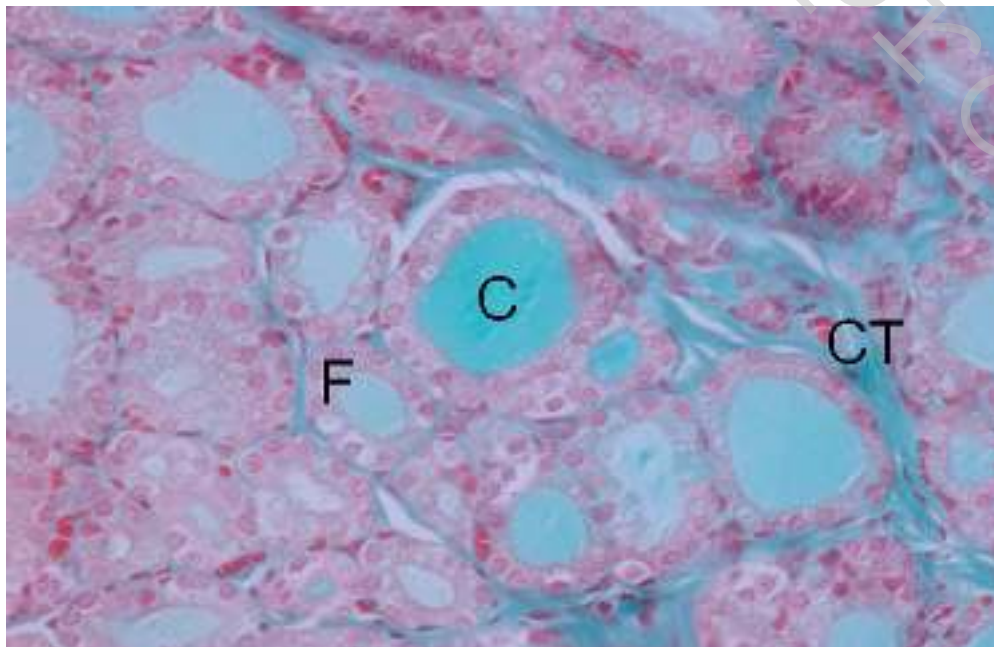
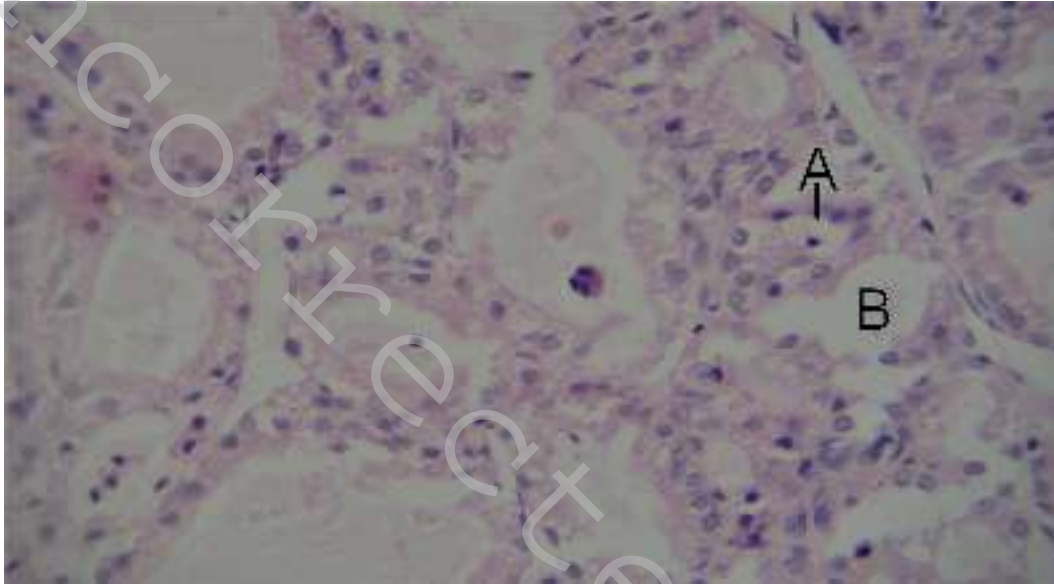


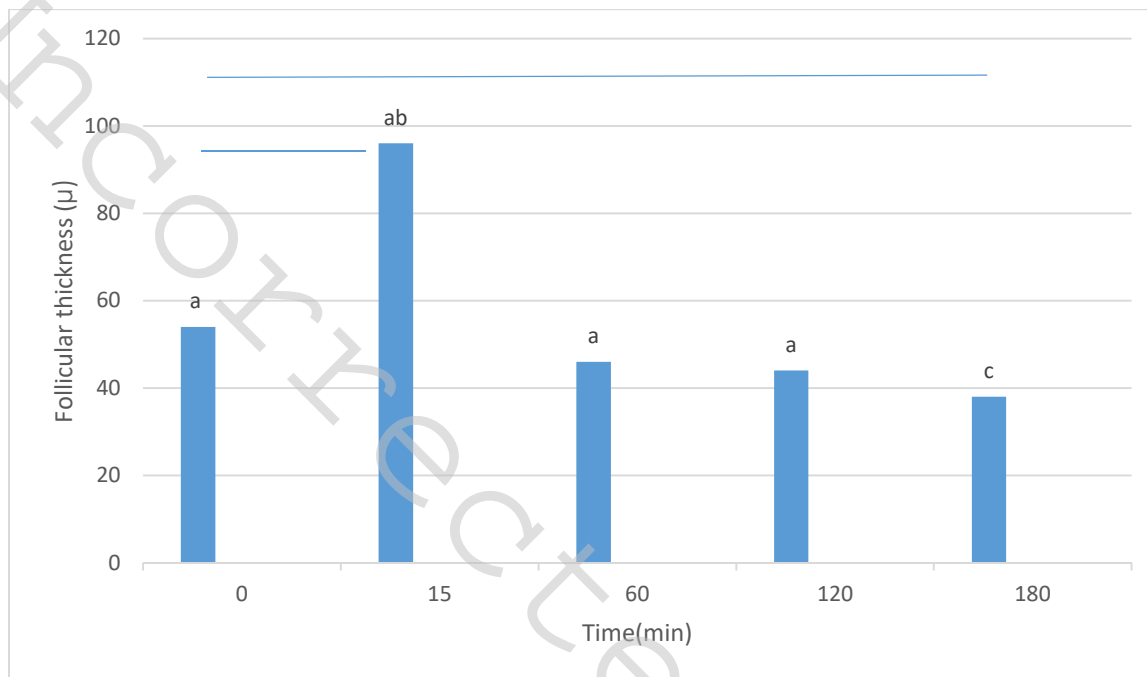
Figure 4: Photomicrograph of thyroid gland from animal exposed to 2100 MHz (group: 180 min)

shows colloid droplets within a TCs (F), coagulated colloid (C) and Connective tissue (CT), Mason trichrome staining $\times 400$.

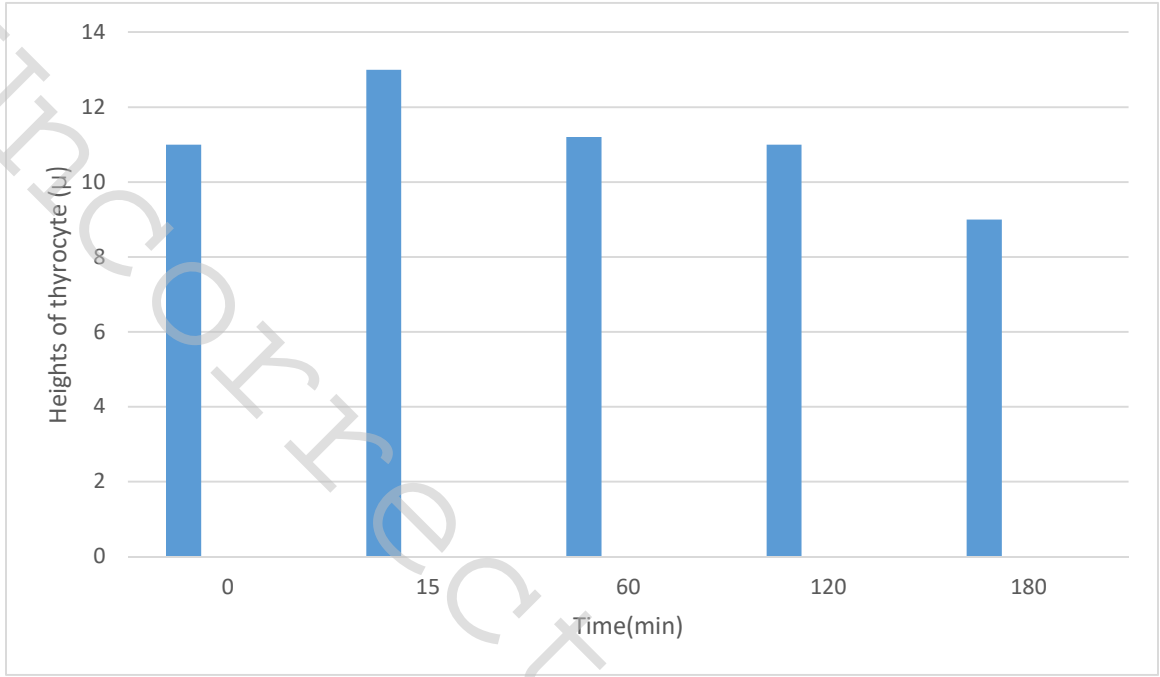


Graph Legends:

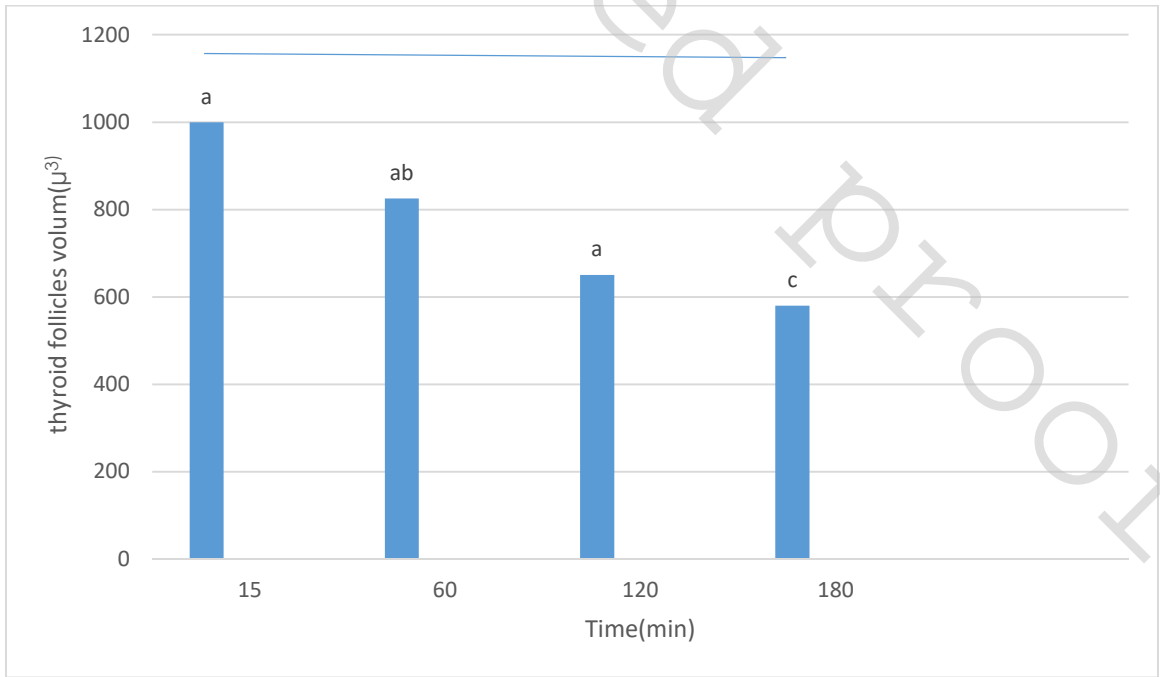
Graph 1: Measurement of the diameters of the thyroid follicles ($p \leq 0.005$).



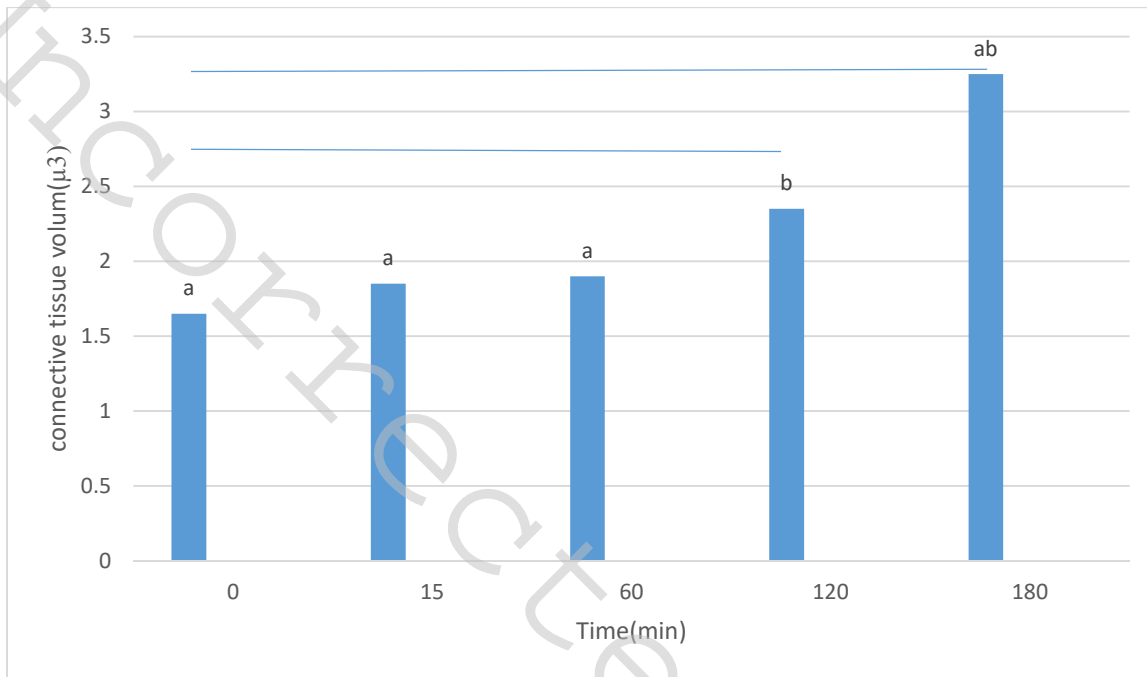
Graph 2: Measurement of the heights of the epithelial follicles ($p \leq 0.005$).



Graph 3: Measurement of the thyroid follicular volume ($p \leq 0.005$).



Graph 4: Measurement of connective tissue volume ($p \leq 0.005$).



عنوان: مطالعه اثرات هیستوپاتولوژی امواج الکترومغناطیس (EMF) بر روی غده تیروئید در رت

خلاصه:

رابطه بین قرار گرفتن در معرض میدان الکترومغناطیسی (EMF) و سلامتی انسان بسیار مهم می باشد. برخی از منابع رایج EMF عبارتند از تلفن همراه، کامپیوتر، روترهای بی سیم (Wi-Fi)، بلوتوث، مایکروویو، دستگاه MRI، اشعه ایکس، اشعه گاما و اشعه ماوراء بنفش. غده تیروئید یکی از در معرض ترین و حیاتی ترین اندام هاست و ممکن است هدف هر نوع تابش الکترومغناطیسی باشد. بنابراین، ما اثرات هیستوپاتولوژیک میدان الکترومغناطیسی (EMF) بر غده تیروئید رت را بررسی کردیم .

در این تحقیق از 35 رت نژاد ویستار سالم استفاده شد. حیوانات به پنج گروه تقسیم شدند و سپس همه حیوانات به مدت 70 روز هر روز به مدت 0، 15، 60، 120، 180 دقیقه در معرض فرکانس 2100 مگاهرتز (4G) قرار گرفتند. حیوانات با CO2 بیهوش شدند. نمونه‌های از غده تیروئید تهیه و با هماتوکسیلین و ائوزین (H&E) و ماسون تری کروم رنگ آمیزی شدند. مطالعات استریولوژیکی بر اساس اصل کاوالیر انجام شد. پس از قرار گرفتن در معرض EMF، کاهش معنی داری ($P < 0.05$) در قطر فولیکول‌های تیروئید، ارتفاع بافت پوششی فولیکول‌ها و حجم فولیکول‌های تیروئید در گروهی که به مدت 3 ساعت تحت تابش امواج قرار داشتند ثبت شد. مطالعه ما نشان داد که در گروه های 2 و 3 ساعت اثرات آسیب بافتی شامل فولیکول های متراکم با کاهش کلونئید، احتقان و گسترش بافت همبند در فضای بینابینی مشاهده شد. علاوه بر آن تشکیل اجسام آپوپتوز در داخل فولیکول ها و همچنین سلول های فولیکولی با هسته های متراکم در غده تیروئید رت ها ی که به مدت 3 ساعت تحت تابش امواج EMF قرار گرفتند مشاهده گردید.

در نهایت به این نتیجه رسیدیم که قرار گرفتن در معرض EMF (4G) برای بیش از 2 ساعت به مدت 70 روز متوالی دارای اثرات

هیستوپاتولوژیک و استریولوژیک در بافت تیروئید در رت می باشد.

کلید واژه: هیستوپاتولوژی، امواج الکترومغناطیس، غده تیروئید

UnCorrected Proof